

**PATIENT**

Rowan Junis

**SPECIES**

Canine

**BREED**

American Bull Terrier Mix

**SEX**

Female Spayed

**AGE**

2013

**WEIGHT**

53.5lbs

**PRESENTING CLINICAL SIGNS**

History: 8/5/21 seen for limping/joint pain in front legs, dx w/oa of elbow and shoulder, no murmur noted. Patient on chronic Proin for incontinence. 8/30/21 presented for bloating/abdominal distension, mild lethargy, eating and drinking ok. Noted mild cyanosis of paws/toe nails. Heart murmur - 2-3/6

Fast scan confirms ascites w/clear straw colored fluid on diagnostic abdominocentesis  
 Enlarged cardiac silhouette. Reverse-d on chest radiograph scan and pulmonary edema  
 Pertinent abnormal PE/Chem/CBC/UA Results: mild elevation in K, otherwise chemistry WNL.  
 Current medications: Furosemide 60mg BID, Vetmedin 5mg BID, Enalapril 15mg BID, AO to DC Proin and Carprofen.  
 STAT: Requested and approved.

**RADIOGRAPHIC FINDINGS** \*NOTE: Images submitted for supplemental information only.  
 Right-sided cardiomegaly. Bronchointerstitial pattern.

**ECHOCARDIOGRAM FINDINGS**

2D, m-mode, color flow and doppler imaging is available. Mild diffuse thickening of mitral valve leaflets with no prolapse into the left atrial lumen. Mild eccentric mitral regurgitation with a mildly dilated left atrium. Normal MR velocity. Borderline LV dimension (LVIdDn 1.77 LVIdSn 1.29) with decreased myocardial function. Septal bounce/bowing. The tricuspid valve appears mildly thickened, with mild to moderate tricuspid regurgitation. Normal TR velocity. The right atrium is moderately dilated. The right ventricle is significantly dilated with significant systolic dysfunction. The pulmonic and aortic valves are normal in morphology and mobility. Normal pulmonic and aortic outflow velocities with laminar flow. No obvious aortic or pulmonic insufficiency. No significant pericardial effusion. No pleural effusion seen. No obvious cardiac masses.

**CARDIAC CHART**

**INTERPRETED BY**

Maggie Machen Lamy, DVM, DACVIM (Cardiology)

**HOSPITAL NAME**

Northwind Animal Hospital

**REFERRING VET**

Dr. Repsher

**INVOICE**

20880

**DATE**

9/3/21

CANINE CARDIAC PARAMETERS	MR VMAX (m/s)	TR VMAX (m/s)	LA/AO (Boon method)	LA/AO (Heart Base; Swe)	FS (%)	EF (%)	EPSS (cm)
<b>NORMAL PARAMETER</b>	4.5-5.5	<2.7	1.3	<1.6	28-40	40-100	<0.6
<b>PATIENT</b>	5.1	2.3	NM	1.3	20	38	NM
CANINE CARDIAC PARAMETERS	HR (BPM)	AV VMAX (m/s)	PV MAX (m/s)	BODY WEIGHT (kg)	LA 2D short axis Base view (cm)	LVIdd Avg; 2D and m-mode short axis (cm)	LVIDs Avg; 2D and m-mode short axis (cm)
<b>NORMAL PARAMETER</b>	50-100	0.7-1.7	0.7-1.6	BELOW	BELOW	BELOW	BELOW
<b>PATIENT</b>	116	1.0	0.73	24	2.7	4.4	3.5
*Normal chamber parameters expressed as a mean value (SD)				3	1.27 (5.3)	2.46 (2.46)	1.36 (5.5)
<b>BODY WEIGHT DEPENDENT PARAMETERS</b>				5	1.40 (4.5)	2.74 (5.2)	1.60 (4.7)
*Note: All measurements based upon multi-modal images and methods. An average value is reported.				10	1.50 (3.8)	3.27 (3.5)	2.06 (3.1)
				15	1.83 (2.0)	3.71 (2.4)	2.43 (2.1)
				20	2.02 (1.9)	4.14 (2.2)	2.80 (2.0)
				25	2.18 (2.4)	4.48 (2.9)	3.10 (2.5)
				30	2.33 (3.3)	4.83 (3.9)	3.39 (3.4)
				35	2.48 (4.3)	5.17 (5.0)	3.69 (4.5)
				40	2.62 (5.2)	5.48 (6.1)	3.96 (5.4)
				50	2.88 (7.1)	6.07 (8.3)	4.46 (7.4)

Adapted from June Boon, Veterinary Echocardiography, 1998  
 Rishniw M and Hollis NE, J Vet Intern Med 2000; 14:429-435  
 Hansson et al, Vet Rad and Ultrasound 2002  
 Bonagura et al. Echocardiography: principles of interpretation, Vet Clin North Am 15:1177, 1995

## INTERPRETATION OF THE FINDINGS & FURTHER RECOMMENDATIONS

Unfortunately, this patient has suspected right ventricular cardiomyopathy with significant right heart dilation and dysfunction. A tricuspid leak is noted which is mild and considered secondary. The velocity is normal, ruling out typical PAH. The left heart is also affected to a lesser extent, with mild LV dysfunction and LA dilation which may reflect a true DCM or may be secondary to RV changes. Regardless the findings confirm CHF as the cause of ascites. It is worth mentioning that extra-cardiac masses would not necessarily be identified on an echocardiogram (ie peripheral pulmonary/vascular mass leading to compression), and ancillary issues contributing to these findings are certainly not ruled out. Consider advanced imaging such as a thoracic CT.

Dilation and dysfunction of the right heart specifically can be primary in nature due to a form of ARVC, or may reflect DCM affecting both sides of the heart. The former is suspected in this case. Consider contributing issues of systolic dysfunction, including a grain free diet.

Institute lifelong medications as recommended as below. If the patient is unstable or experience collapse or worsening symptoms at home, 24 hours monitoring in addition to oxygen support and diuretic therapy should be considered. A baseline ECG is recommended regardless due to high risk for rapid AF or VT in the future. **It is important to note that this patient is at low risk of pulmonary edema, and this is unlikely. Consider a radiologist evaluation of the films for further pulmonary interpretation.**

Prognosis is poor at this stage with most dogs succumbing to CHF in less than 6 months. There is high risk for recurrent congestive heart failure, malignant arrhythmias (AF, VT), collapse and/or sudden death in the future even on medications.

Omega fatty acid supplementation and mild salt restriction may be of some long-term benefit.

Elective anesthesia is not advised.

Monitor for development of a cough, labored breathing, exercise intolerance or collapse episodes. Monitoring of sleeping breathing rates is recommended as the best way to screen for CHF going forward.

## PLAN

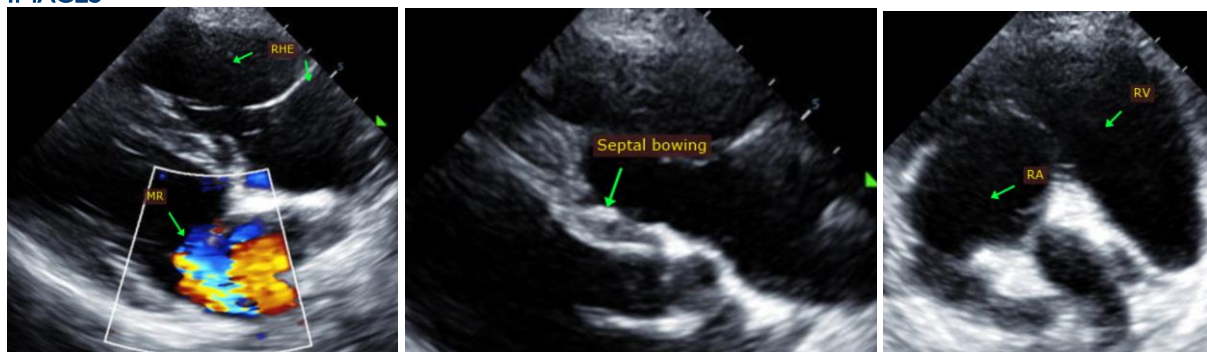
Consider hospitalization for supportive care if indicated. A therapeutic abdominocentesis should be performed if inappetence or discomfort develops. Continue Lasix as prescribe. DOSE INC: Administer heart muscle support Pimobendan (Vetmedin) 7.5mg PO q12h. Institute Spironolactone 1-2mg/kg PO q12h (available in 25 and 50mg tablets). Once BP is documented >130mmHg, continue ACEI 0.5mg/kg PO q12h.

Highly recommend ECG/BP as a baseline. Consider hydrocodone with homatropine if needed for quality of life, 0.2 – 0.4 mg/kg PO up to q4-6 hours PRN for cough (available in 5/1.5mg tablets or 5mg/5ml solution). Diet history with avoidance of BEG options. Institute taurine supplementation 1000mg PO q12h.

Monitor renal values, BP in 1-2 weeks, then every 3-4 months lifelong. Consider advanced imaging, radiologist review, etc.

Recommend conservative monitoring with a recheck echocardiogram in 6 months, sooner if any development of clinical signs.

## IMAGES



**The information and recommendations provided are based on the images presented by the referring veterinarian. No evaluation can be communicated regarding pathology that was not visible in the image/video clips provided.**

Thank you for this referral. This report was generated using transcription software, and minor dictation errors may be present. If the clinical or image interpretation does not parallel your findings or if I can be of any further assistance please contact me.

**Maggie Machen Lamy, DVM**  
**Diplomate of the American College of Veterinary Internal Medicine (Cardiology)**  
**info@sonopath.com**